

# Clinical Application and Usefulness of Multi-Slice View in Fetal Echocardiography

Hye-Sung Won, M.D., Sun Kwon Kim, M.D., Jin-Young Ma, M.D., Jae-Yoon Shim, M.D., Pil Ryang Lee, M.D., Ahm Kim, M.D.  
Department of Obstetrics and Gynecology, College of Medicine, University of Ulsan, Asan Medical Center, Seoul, Korea

## INTRODUCTION & OBJECTIVE

The structure of fetal heart is difficult to evaluate because of rapid movement, fetal position and complexity. Recently Multi-Slice View (MSV) in fetal echocardiography is used to evaluate the anatomy of the normal heart and to help elucidate complex heart disease. MSV allows simultaneous display of multiple sequential parallel planes, particularly septal defect and great vessel alignment. In this study, we introduce the clinical application and usefulness of Multi-Slice View for screening of normal heart structure and fetal heart anomalies. We also discuss the benefits compared to conventional two-dimensional ultrasonography.

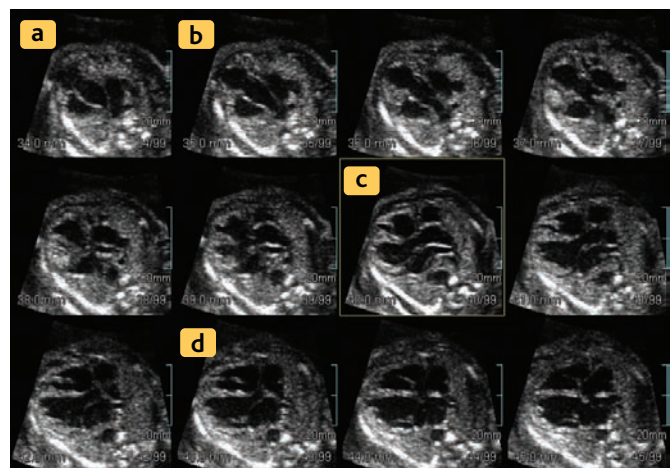
## METHODS

We performed prenatal ultrasonography on 35 fetuses with congenital heart anomalies, at various gestational ages, using ACCUVIX XQ (MEDISON Co.,Ltd. Korea) at Asan Medical Center between June 2004 and Oct. 2005.

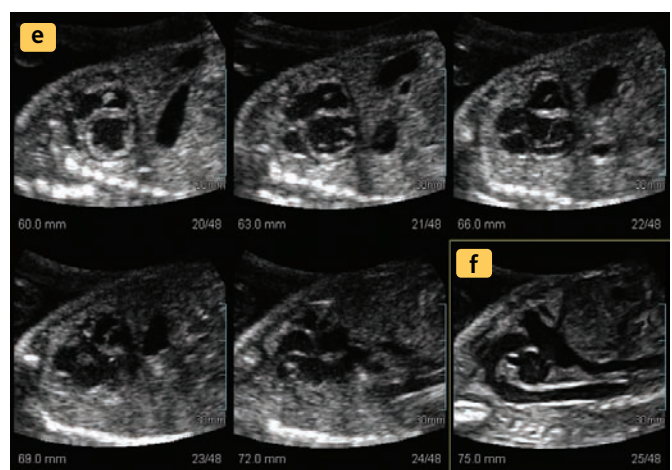
## RESULTS

We obtained abnormal views of 35 fetuses using MSV which provides excellent views of great vessel alignment and different types of septal defects and allows a simultaneous display of multiple sequential parallel planes of the fetal structures. The spatial relationships and communications of the four-chamber, three vessel and the outflow tract can be quickly identified to screen for congenital heart defects.

### Normal Axial Plane



### Normal Sagittal Plane

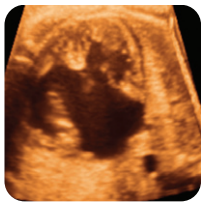

### NORMAL HEART VIEW:

*In a MSV of a fetal heart, it is possible to get any plane simultaneously. The starting plane is three vessel view(a), following by RVOT(b), LVOT(c) and four-chamber view. Once a plane of the four chamber view is acquired, the plane is rotated until the aortic arch is displayed in the original plane of acquisition. It enables demonstrating the arch view(e-f).*

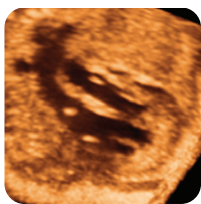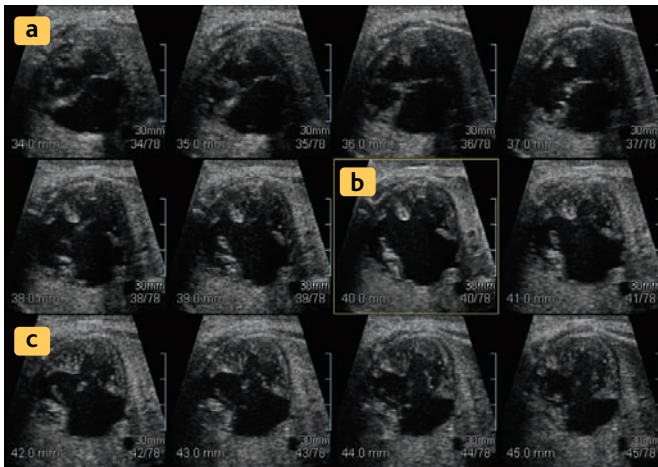
## CONCLUSIONS

The 3D XI is an innovation diagnostic tool that incorporates CT- and MRI-like technologies with ultrasound, 3D XI provides additional information in fetal echocardiography, particularly regarding the alignment of great vessels and mapping of septal defects. The data selection and storage function permit faster, more objective and more accurate diagnoses.



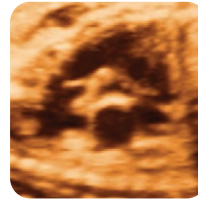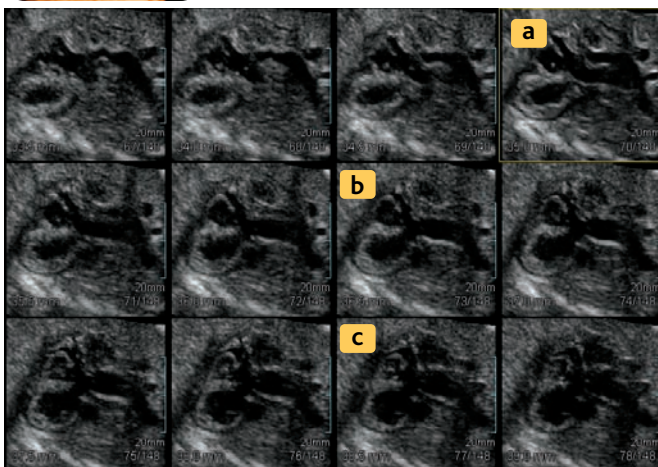
### CASE 1. AVSD:

*This image shows a common atrioventricular valve. Morphological changes a opening and closing of common valve could be observed clearly and in detail through out the cardiac cycle. (a~c)*



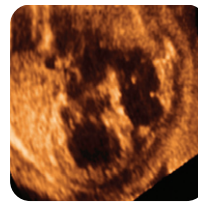
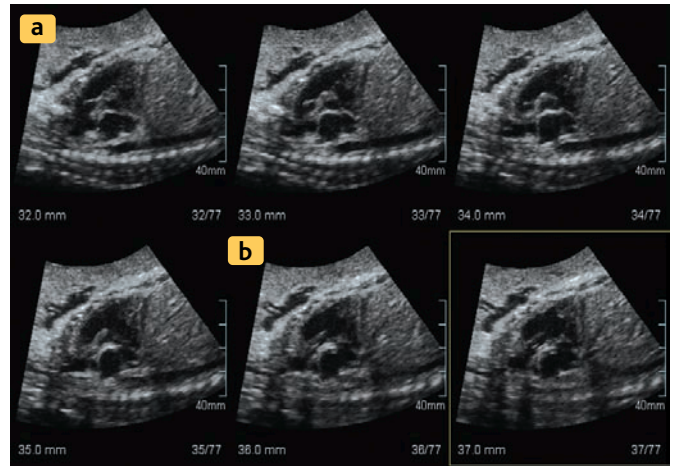
### CASE 2. TGA:

*The pulmonary artery connects to the left ventricle (a) and the aorta connects to the right ventricle (b); the vessel leave the ventricles parallel to each other(c). MSV can facilitate understanding of the spatial relationship between great vessels.*



### CASE 3. DORV (TAUSSIG-BING TYPE):

*The pulmonary artery and aorta connect preferentially to the right ventricle with the pulmonary artery overriding the ventricular septum. The aorta parallels to the front of the pulmonary artery (a~b).*



### CASE 4. EBSTEIN ANOMALY:

*MSV showed the location of the Tricuspid valve during cardiac cycle. At maximal contraction in the systolic phase, TV was displaced lower level than in the diastolic phase. At this time, RV was nearly invisible (a~c).*

